

Case Report

Infantile Bullous Pemphigoid: Two Case Reports and Literature Review

Youssef Monia^{1*}, Korbi Mouna¹, Soua Yosra¹, Mohamed Meriem¹, Akkari Hayet¹, Hammami Sabeur², Hadhri Rym³, Belhadjali Hichem¹ and Zili Jameleddine¹

¹Departement of Dermatology, Fattouma Bourguiba Hospital, Tunisia

²Department of Pediatric, Fattouma Bourguiba Hospital, Tunisia

³Department of Anatomopathology, Fattouma Bourguiba Hospital, Tunisia

***Corresponding author**

Youssef Monia, Department of Dermatology, Fattouma Bourguiba Hospital, 5000 Monastir, Tunisia, Tel: + 21673461144; Fax: +21673460678; Email: monia.youssef@gmail.com

Submitted: 01 May 2014

Accepted: 06 May 2014

Published: 06 June 2014

Copyright

© 2014 Monia et al.

OPEN ACCESS**Keywords**

- Infantile
- Pemphigoid
- Bullous
- Therapy

Abstract

Bullous pemphigoid is an autoimmune sub epidermal blistering dermatosis that is uncommon in childhood. We report two cases of children with bullous pemphigoid. The first one was a case of a 4-month-old female infant, whereas the second is of a 3-month-old male infant. The two cases presented clinical and laboratory data for the confirmatory diagnosis of bullous pemphigoid. Opportunely we review the clinical, immunological, therapeutic and prognostic features of this pathology in children.

INTRODUCTION

Bullous Pemphigoid (BP) is an acquired disease that belongs to the group of autoimmune subepidermal bullous disorders [1]. It features circulating autoantibodies against distinctive skin's basal membrane antigens and adjacent mucous membranes' antigens [1,2]. It is uncommon for the disease to begin during childhood and even more during infancy [1]. The clinical, histopathological and immunopathologic characteristics of this disease during childhood overlap with those in the adult form [3,4]. However, some peculiarities are present in childhood BP [5,6]. We report two new cases of infantile bullous pemphigoid. The purpose of our study was to review the clinical, histopathologic, immunologic, and therapeutic aspects of bullous pemphigoid in children.

CASE PRESENTATION**Case N°1**

An infant, 4 months old female, with no particular history especially no immunization before eruption, had a generalized erythematous bullous febrile eruption on palms and soles lasting for 15 days. She was treated by oral antibiotic without improvement. On physical examination, the patient was afebrile. On dermatological examination, we noted multiple bubbles of different age on erythematous skin widespread all over the skin areas (Figure 1). These bubbles were strained with a negative Nikolsky sign. Mucous membranes were healthy. A skin biopsy showed a dermo-epidermal cleavage (Figure 2A). Direct Immunofluorescence (DIF) demonstrated linear deposits of C3 (Figure 2B) and IgG (Figure 2C) in the dermo-epidermal junction. The biological finding didn't show any abnormalities especially

any eosinophilia. Systemic corticosteroid at a dose of 1mg/kg/day was established with a favorable outcome. Within six months we were able to gradually stop oral corticosteroids without recurrence of skin lesions.

Case N°2

A healthy male infant, 3 months old, had developed papules and pustules initially on palms and soles, with progressive

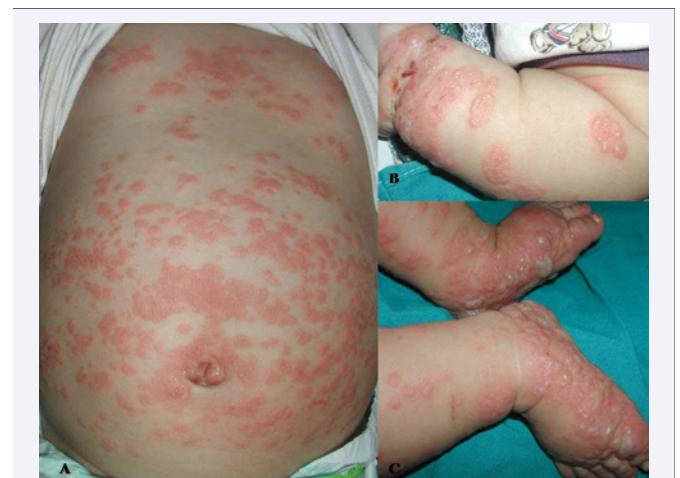

Figure 1 Multiple erythematous papules and plaques all over the anterior aspect of the trunk (A). vesiculo-bullous lesions all over erythematous skin localized on the upper (B) and lower extremities (C).

involvement of trunk, limbs and head (Figure 3) with negative Nikolsky sign. The oral and genital mucous membranes were the seat of some erosion. He didn't have any vaccination before the beginning of the eruption. Complete blood count showed hypereosinophilia. DIF detected the presence of linear IgG and C3 deposits along the subepidermal basal membrane zone. The diagnosis of BP was made. The infant was initially treated with steroids for 3 weeks, but with no improvement. Association with dapsone at a dose of 25 mg / day was made. One month later, all lesions have disappeared, that led us to stop gradually dapsone within two months and corticosteroids after 6 months. There was no relapse during a follow-up of one year.

DISCUSSION

The first case of juvenile BP confirmed by DIF was published in 1970 [4]. Since then, there has been a notable increase in published cases. Currently there are fewer than 100 cases reported in childhood, a dozen in infants [4,7]. The precise incidence of BP in children and other bullous dermatoses in childhood are unknown [4,6]. Waisbourd-Zinman et al reviewed the literature in 2008 and identified only 79 cases of childhood BP [7]. Some authors have noted that BP in infancy may present within hours to days after vaccinations such as tetraoq (combined tetanus, diphtheria, Bordetella pertussis, and

poliovirus) and hepatitis B vaccination [8]. Among the study done by Waisbourd-Zinman there were two infants who developed the disease within 2 weeks after receiving the tetraoq plus hepatitis B vaccination, although in this same study there was an infant who had BP without ever receiving immunization which was the same case of our two patients [7]. So, Waisbourd-Zinman et al concluded that because of the high rate of vaccinations in the first year of life, it is not feasible to establish an association between vaccination and BP [7]. Even though some authors consider that there is no sex predilection in childhood BP [9], Waisbourd-Zinman et al consider that BP in children has a female predominance throughout all ages [7]. The age of onset varies from two months to 16 years [9]. Two peaks of incidence of BP in childhood were observed: in the first year of life as our two patients and at the age of 8 years [7]. The clinical characteristics of this disease during childhood overlap with those in the adult form [3,4]. However, some peculiarities are present in childhood BP [4-7]. Palmoplantar lesions are typical of childhood BP [7,10], especially in children less than one year ⁷, and these were the initial lesions in our reported cases. The widespread involvement predominates in infants [10]. As it was the case for our two infants. Mucosal involvement is most commonly found in children older than 1 year [7]. Nevertheless our second case exhibited lesions on oral and genital mucous membranes. Thus, several clinical features of the disease differ between infants and older children. In infants younger than 1 year, BP presented with blisters on the palms, soles, and face [7]. However such a presentation in older children was described in a minority of cases [7]. Genital involvement was seen rarely in infants with BP whereas in older children it was found in almost half of the cases [7]. Waisbourd-Zinman et al reported that among cases of childhood BP, there was a subgroup of localized genital involvement, almost exclusively reported in girls with a single exception of a 3-year-old boy with scrotal lesions among other involved areas which was similar to our second patient [7]. The pathogenetic mechanism that underlies these age-related clinical differences is unknown but could be attributed to possible age-dependent expression of BP antigen in various body skin areas [7]. Diagnosis is based on clinical, histopathological and DIF [10]. Nemeth et al proposed the following diagnostic criteria for childhood BP [6]: (1) age 18 years or younger; (2) clinical appearance of tense bullae; (3) histopathologic finding of a subepidermal blister with eosinophilia; and (4) DIF showing linear deposition of IgG or C3 as the major immunoreactants at the basement membrane zone or a positive indirect immunofluorescence result showing circulating IgG antibasement membrane zone autoantibodies [6]. Our two patients satisfy these 4 criteria. BP can simulate various dermatoses and be clinically indistinguishable from other bullous diseases of childhood, such as dermatitis herpetiformis, acquired epidermolysis bullosa, bullous systemic lupus erythematosus or linear IgA bullous dermatosis [10]. The atypical clinical presentation of BP in childhood may also lead to the diagnosis of atopic dermatitis [11,12]. Our dermatology department reported through literature in 2008 a case of a childhood vesicular pemphigoid mimicking severe atopic dermatitis [11]. It was another similar case of childhood vesicular pemphigoid in a 16-year-old boy [12]. In addition to typical clinical features, bullous pemphigoid is also defined by characteristic histopathologic and immunologic criteria which showed spongiotic dermatitis with

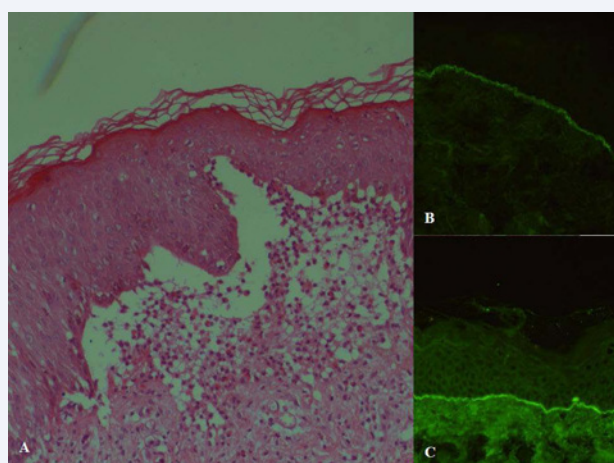


Figure 2 (A) a subepidermal blister containing inflammatory cells (HE X100). Direct immunofluorescence showing a linear deposition of C3 (B) and IgG (C) along the basement membrane.

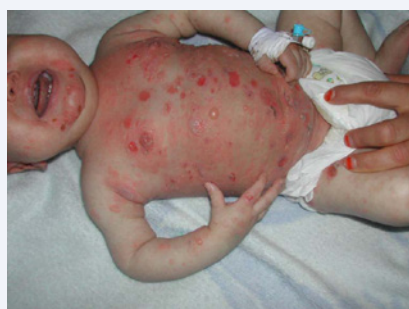

Figure 3 Diffuse papules, vesicles, bullae and erosions on the trunk, limbs and face.

subepidermal bullae rich in neutrophils and eosinophils [10]. DIF detected in the most of cases a linear IgG and C3 deposits along the subepidermal basal membrane zone which was reported in our two patients [10]. IgA and IgM may also be present [7]. In addition, laboratory parameters were not significantly different in infantile or childhood BP except for a more frequent IgM deposition in childhood BP [7]. The course of this latter is usually indolent with rare relapses [7,10]. Even so, the disease may be life threatening, particularly when appropriate management is delayed [13]. This leads us to speak about the different treatments of PB. Waisbourd-Zinman et al reported a great variety of immunosuppressive treatments and according to this study the response to therapy in infantile BP is rapid [7]. Classically, the treatment of choice is systemic corticosteroids at a dose of 1 to 2 mg/kg/day of prednisone, only enough to control the disease which was the case of our first patient [6,10]. The healing occurs after a few weeks or months of treatment [4]. Dapsone at the dose of 4 mg/kg/daily may be associated to systemic corticosteroids to induce remission as the case of our second patient [7,10]. However spontaneous recovery was also reported by some authors [7]. Intravenous immunoglobulin [7], intravenous pulse methylprednisolone (30 mg/kg/d for 3 consecutive days) followed by repeated intravenous immunoglobulin (2 g/kg every 2 weeks) and oral mycophenolate mofetil (500-600 mg/m²/d) [7], cyclosporine [7], sulfapyridine [7] and erythromycin [5] have been tried with encouraging results especially in the cases with resistance to systemic corticosteroids. In addition, Waisbourd-Zinman et al reported that systemic corticosteroids were used more frequently in infantile BP than childhood BP which was explained by the higher rate of generalized involvement in infants [7].

CONCLUSION

Nevertheless much more common in adults, BP may rarely occur in infants and children. The histologic and immunologic features are identical to those of the disease in adults, but the clinical features may differ from those seen in the adult patient. Our reported cases confirmed most of the characteristics reviewed in the literature.

REFERENCES

- Schmidt E, della Torre R, Borradori L. Clinical features and practical diagnosis of bullous pemphigoid. *Immunol Allergy Clin North Am*. 2012; 32: 217-232.
- Cunha PR, Barraviera SR. Autoimmune bullous dermatoses. *An Bras Dermatol*. 2009; 84: 111-124.
- Hafiji J, Bhogal B, Rytina E, Burrows NP. Bullous pemphigoid in infancy developing after the first vaccination. *Clin Exp Dermatol*. 2010; 35: 940-941.
- Barreau M, Stefan A, Brouard J, Leconte C, Morice C, Comoz F, et al. [Infantile bullous pemphigoid]. *Ann Dermatol Venerol*. 2012; 139: 555-558.
- Oranje AP, Vuzevski VD, van Joost T, ten Kate F, Naafs B. Bullous pemphigoid in children. Report of three cases with special emphasis on therapy. *Int J Dermatol*. 1991; 30: 339-342.
- Nemeth AJ, Klein AD, Gould EW, Schachner LA. Childhood bullous pemphigoid. Clinical and immunologic features, treatment, and prognosis. *Arch Dermatol*. 1991; 127: 378-386.
- Waisbourd-Zinman O, Ben-Amitai D, Cohen AD, Feinmesser M, Mimouni D, Adir-Shani A, et al. Bullous pemphigoid in infancy: Clinical and epidemiologic characteristics. *J Am Acad Dermatol*. 2008; 58: 41-48.
- de la Fuente S, Hernández-Martín Á, de Lucas R, González-Enseñat MA, Vicente A, Colmenero I, et al. Postvaccination bullous pemphigoid in infancy: report of three new cases and literature review. *Pediatr Dermatol*. 2013; 30: 741-744.
- Fisler RE, Saeb M, Liang MG, Howard RM, McKee PH. Childhood bullous pemphigoid: a clinicopathologic study and review of the literature. *Am J Dermatopathol*. 2003; 25: 183-189.
- Reis-Filho EG, Silva Tde A, Aguirre LH, Reis CM. Bullous pemphigoid in a 3-month-old infant: case report and literature review of this dermatosis in childhood. *An Bras Dermatol*. 2013; 88: 961-965.
- Belhadjali H, Youssef M, Njim L, Chaabane S, Sriha B, Chakroun M, et al. Childhood vesicular pemphigoid mimicking severe atopic dermatitis: a case report. *Cutis*. 2009; 83: 182-184.
- Geyer AS, Zillikens D, Skrobek C, Cohen B, Anhalt GJ, Noursari HC. Vesicular pemphigoid in a 16-year-old boy. *J Am Acad Dermatol*. 2003; 49: 722-724.
- Kuenzli S, Grimaître M, Krischer J, Saurat JH, Calza AM, Borradori L. Childhood bullous pemphigoid: report of a case with life-threatening course during homeopathy treatment. *Pediatr Dermatol*. 2004; 21: 160-163.
- Schmidt E, della Torre R, Borradori L. Clinical features and practical

Cite this article

Monia Y, Mouna K, Yosra S, Meriem M, Hayet A, et al. (2014) Infantile Bullous Pemphigoid: Two Case Reports and Literature Review. *J Dermatolog Clin Res* 2(4): 1029.